

## Case Report

**Surgical Removal of lipoma from an area with tattooed skin**

Francesco Inchingolo<sup>1,4</sup>, Marco Tatullo<sup>2</sup>, Fabio M. Abenavoli<sup>3</sup>, Massimo Marrelli<sup>4</sup>, Alessio D. Inchingolo<sup>5</sup>, Roberto Corelli<sup>6</sup>, Andrea Servili<sup>6</sup>, Angelo M. Inchingolo<sup>7</sup>, Gianna Dipalma<sup>4</sup> ✉

1. Department of Dental Sciences and Surgery, University of Bari, Bari, Italy
2. Department of Medical Biochemistry, Medical Biology and Physics, University of Bari, Bari, Italy
3. Department of "Head and Neck Diseases", Hospital "Fatebenefratelli", Rome, Italy
4. Department of Maxillofacial Surgery, Calabro dental, Crotona, Italy
5. Department of Dental Sciences and Surgery, University of Bari, Bari, Italy
6. Department of Maxillofacial Surgery, University of Bari, Bari, Italy
7. Department of Surgical, Reconstructive and Diagnostic Sciences, University of Milano, Milano, Italy

✉ Corresponding author: Prof. Francesco INCHINGOLO, Piazza Giulio Cesare - Policlinico 70124 - Bari. E-mail: f.inchingolo@tin.it; f.inchingolo@doc.uniba.it. Tel.: 00390805593343 - Infoline: 00393312111104.

Received: 2010.09.09; Accepted: 2010.11.20; Published: 2010.11.22

**Abstract**

The presence of tattoos on the skin of people of all ages is on the rise. On occasion, the tattoo is in close proximity to an area which has to undergo a surgical operation, therefore why not using the tattoo itself to cover the cicatrix?

The case we treated was that of a 39 year old female who, for a couple of years, had a large lipoma on her right shoulder which she never treated because it was beneath a large tattoo. During the surgical treatment of the lipoma, we followed the exact lines of the tattoo itself thus obtaining precise access for lipoma removal which minimized visible post operative cicatrix while maintaining the original tattoo design.

No similar case was found in literature.

Key words: Lipoma; Tattoo; Surgical cicatrix

**INTRODUCTION**

The presence of tattoos on the skin of people of all ages is on the rise.

Many studies have been done of the tattooed population. The Journal of the American Academy of Dermatology published the results of a telephone survey which took place in 2004: it found that 36% of Americans ages 18-29, 24% of those 30-40 and 15% of those 41-51 had a tattoo. Men are just slightly more likely to have a tattoo than women (15% versus 13%).<sup>1</sup>

Tattoos have different aspects, both psychological and social, which attract more and more people; therefore, meeting people with one or more tattoos is increasingly common in our profession. Sometimes, as happened recently during our observations, the tattoo is in close proximity to an area which has to

undergo a surgical operation, therefore why not using the tattoo itself to cover the cicatrix?

**CASE REPORT**

The case we treated was that of a 39 year old Caucasian female, with a large lipoma located on her right shoulder which she left untreated because it was beneath a large tattoo (Fig.1): the lipomatous formation was 8 cm in diameter and the histology of the specimen reported benign lipoma, not tethered to the skin but inserted into the deepest subcutaneous layer, adherent to the muscle fascia. Our patient was afraid of tattoo degradation as a risk associated with surgical removal of the lipoma.

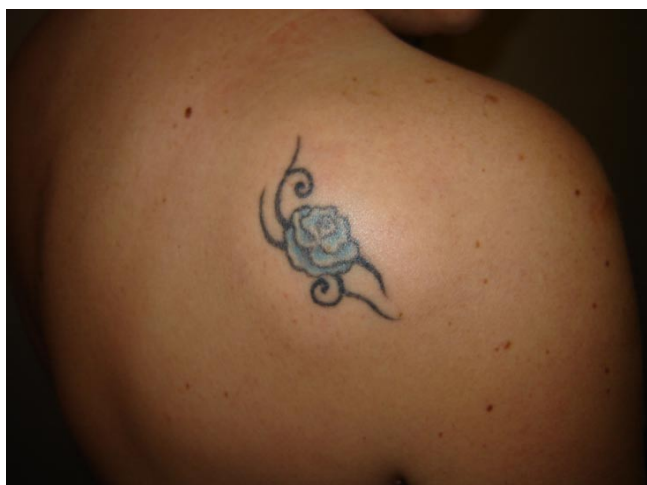
Consequently, in order to meet the need of our patient of removing the lipomatous formation while keeping the tattoo intact, during the surgical treatment of the lipoma, we followed the exact lines of the tattoo itself thus obtaining precise access for lipoma removal which minimized visible post operative cicatrix while maintaining the original tattoo design.

The area was infiltrated with 1% Xylocaine and Epinephrine 1:200.000 for adequate anesthesia and hemostasis. The skin was incised in the tattoo line with a scalpel blade no. 15. The wall of the lipomatous lesion was identified and was isolated from the surrounding layers and freed from the tenacious adhesions with the muscular plane. The procedure involved hemostasis obtained with manual pressure and sterile dressing, and three-layer sutures to eliminate the space remaining after lesion removal. A first deep layer with Vicryl 3-0, slightly affecting the muscle fascia. A second subcutaneous deep layer with Monocryl 4/0 and a subderm layer with Monocryl 5/0.

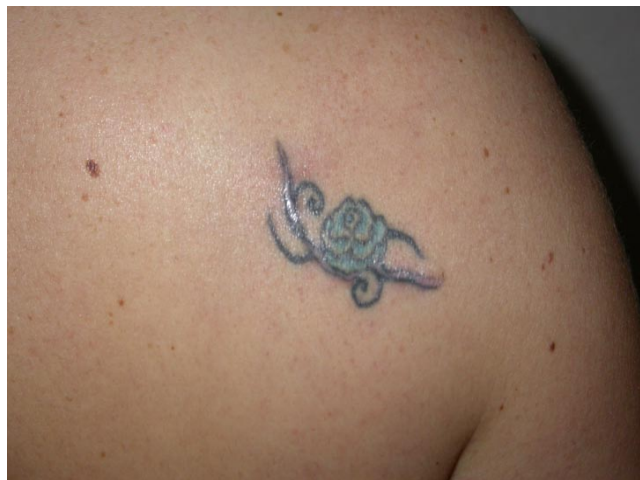
We used interrupted sutures. The epithelial surface was closed with Dermabond. We recommended Light compression with Reston square for 4 days was applied followed by the use of a sticking plaster (Leukoplast®).

In the postoperative phase, we recommend the use of a silicone gel, to be applied morning and evening for at least 3 months. No other procedures were used, because complete wound healing was achieved.

Post operative photos were taken after 4 months and no sign of the surgical cicatrix was visible and the original tattoo design was kept intact (Fig.2). Obviously, the Patient was fully satisfied with the result obtained.



**Figure 1** Pre-operative photo of the lipomatous formation with the tattoo.



**Figure 2** Four months post-operative result.

## DISCUSSION AND CONCLUSIONS

No similar case of surgical removal of lipoma from an area with tattooed skin using this aesthetic procedure was found in literature. The intent of the case study is to highlight the use of pre-existing tattoo outline to minimize the appearance of surgical incisions. This procedure, in our opinion, camouflages a future scar. If we consider the increasing number of people with a tattoo, we could recommend to use precolored lines to hide future scars.

## CONSENT STATEMENT

Written informed consent was obtained from the patient for publication of this case report and accompanying images. A copy of the written consent is available for review by the Editor-in-Chief of this journal.

## AUTHORS' CONTRIBUTIONS

FI, FMA, AS and RC participated in the surgical treatment and in the follow-up examinations. MT drafted the manuscript and revised the literature sources. MM and GD participated in the follow-up examinations.

ADI revised the literature sources. AMI managed the data collection and contributed to writing the paper. All authors read and approved the final manuscript.

## COMPETING INTERESTS

The authors declare that they have no competing interests.

## REFERENCES

1. Laumann AE, Derick AJ. Tattoos and body piercings in the United States: a national data set. *J Am Acad Dermatol.* 2006;55(3):413-21.